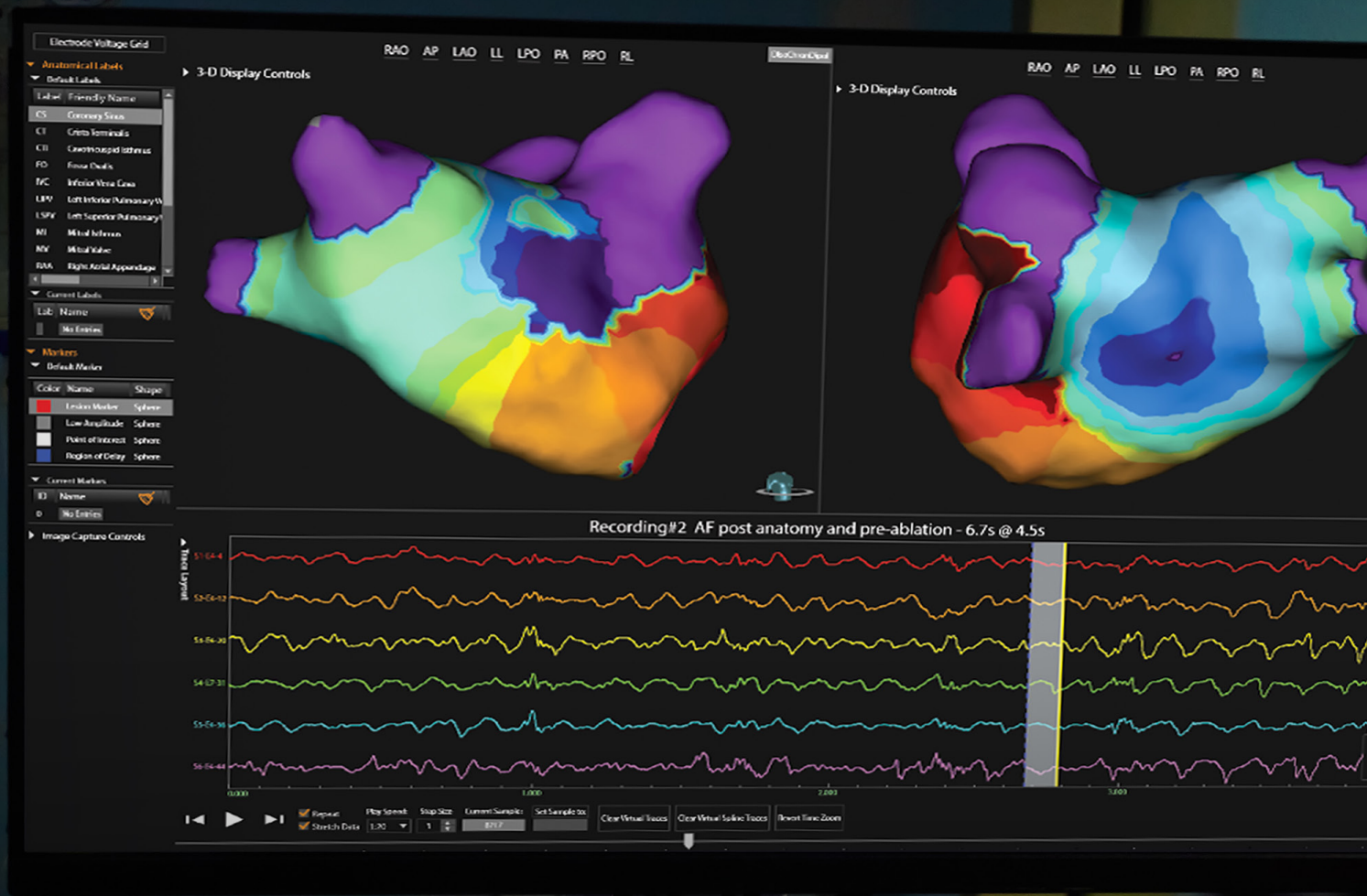

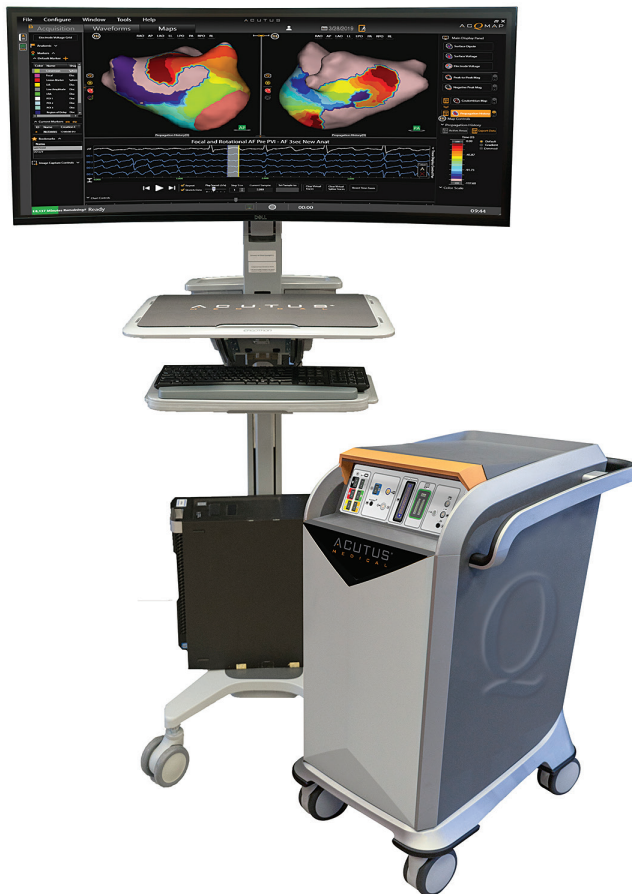Acutus Medical Clinical Compendium Ventricular Tachycardia Abstracts

ACUTUSTM
M E D I C A L

ACQMAP™

HIGH RESOLUTION IMAGING
+ MAPPING SYSTEM



3D IMAGING, MAPPING & NAVIGATION SYSTEM

- 3D ultra-high resolution ultrasound imaging
- Full chamber single beat mapping capability
- Enable mapping of stable and unstable rhythms

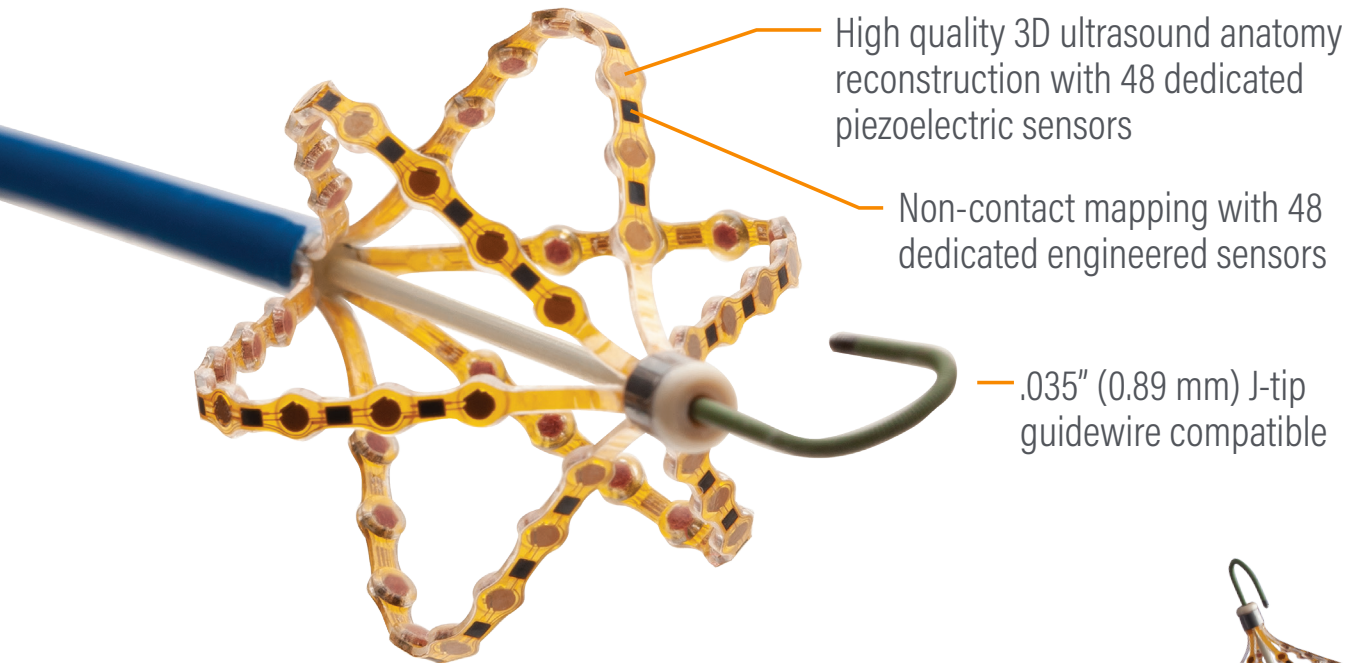
STANDALONE OPEN PLATFORM SYSTEM

- Compatible with a wide range of diagnostic and therapeutic tools
- Maintain customer preference for ablation and mapping catheters

MULTIPLE MAPPING MODES — BUILT TO MAP EVERY BEAT

- Contact mapping for simple anatomical ablations
- Hover mapping with SuperMap for multi-morphic, repetitive rhythms
- Single position non-contact mapping of unstable arrhythmias

Next Generation AcQMap 3D Imaging and Mapping Catheter Improved Handling and Deliverability



ACQMAPTM 3D IMAGING + MAPPING CATHETER

- The world's only integrated high-resolution ultrasound imaging and non-contact mapping catheter
- Optimal maneuverability with the AcQGuide MAX steerable sheath
- Improved handling¹ with enhanced torquability
- Enhanced deliverability with a .035" guidewire



The AcQMap catheter is not indicated for human use in the ventricle; preclinical work only.

CONTENTS

VENTRICULAR TACHYCARDIA ABSTRACTS

- 1 High-resolution Real-time Left-ventricular Endocardial Activation-repolarization Mapping in an *In-vivo* Canine Model of Drug-induced Long-QT 1 Syndrome and Torsades De Pointes.
- 2 Accuracy of Non-Contact Ultrasound-Based Left Ventricular Anatomy and Whole-Chamber Charge Density Mapping for Identifying Ischemic Scar in a Sheep Model
- 3 Left Ventricular Substrate Characterization by Conduction Velocity in Sinus Rhythm, Ventricular Pacing, and Ventricular Fibrillation
- 4 Comparison of Intracardiac Non-Contact Calculated Ventricular Electrograms to Measured Contact Electrograms During Mapping: Validating SuperMap Technology

VENTRICULAR TACHYCARDIA ABSTRACTS

ACUTUS™
M E D I C A L

ACQMAP CLINICAL COMPENDIUM

High-resolution Real-time Left-ventricular Endocardial Activation-repolarization Mapping in an *In-vivo* Canine Model of Drug-induced Long-QT 1 Syndrome and Torsades De Pointes.

HRS Abstract 2021 D-XXXX-XXX. *Heart Rhythm* Vol. 18, No. 7, July Supplement 2021, SXXX.

Rachel M.A. ter Bekke, MD, PhD, Nathan Angel, Annelies Vanderper, PhD, Tim Corvi, David J. Gallacher, Henk J. van der Linde, PhD and Paul G. A. Volders, MD, PhD. Maastricht University Medical Centre - Cardiology, , Acutus Medical, Carlsbad, CA, Janssen Pharmaceutica, Beerse, Belgium, CARIM/Cardiology, Maastricht, Netherlands.

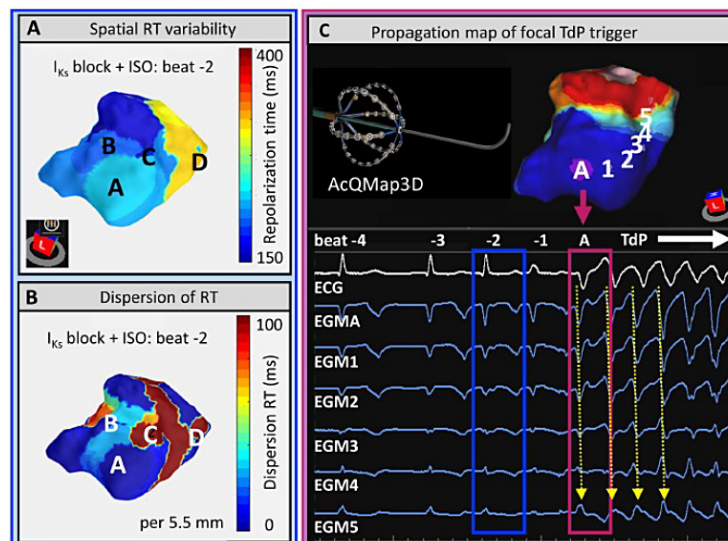
Background: Congenital loss of function or drug-induced inhibition of I_{Ks} causes repolarization lability, predisposing to QT prolongation (LQT1) and sympathetically-evoked torsades de pointes (TdP). High-resolution *in-vivo* mapping of endocardial activation-repolarization times (AT, RT), gradients and focal excitation conspiring to TdP in LQT1 is lacking.

Objective: To study arrhythmogenic mechanisms of TdP in a canine model of drug-induced LQT1 using realtime and high-resolution electroanatomical mapping.

Methods: I_{Ks} inhibition (HMRI556 0.025-0.05 mg/kg/min) was applied in three fentanyl/etomidate anesthetized dogs; anesthesia to maintain near-normal autonomic responsiveness. The AcQMap3D noncontact imaging and mapping catheter (Acutus Medical, US) was positioned in the LV. Isoproterenol (1.25-2.5 mcg/kg) induced TdP. AT, RT (Wyatt), RTmax-min (ΔRT), local RT dispersion (per 5.5 mm) and TdP initiation/propagation were studied.

Results: I_{Ks} block prolonged QTc by 40% (386±22 ms) and mean RT by 44% (309±20 ms), as recorded with the AcQMap3D catheter (AT/RT errors 2.9±4.0/5.4±6.7 ms; cross-correlation 1.0±0.1; time difference 0.8±1.8 ms). ΔRT increased by 23% (85±7 ms) and max local RT dispersion by 19% (80±9 ms). Isoproterenol induced regional RT shortening (base>apex) and beat-to-beat instability, increasing ΔRT significantly by 122% (189±62 ms) and local RT dispersion by 91% (153±51 ms; Figure). Focal triggers of TdP emerged from regions bordering high RT dispersion, driving reentrant excitation.

Conclusion: High-resolution mapping in an *in-vivo* LQT1/TdP model uniquely identifies spatiotemporal RT instabilities, focal excitation and TdP.



Accuracy of Non-Contact Ultrasound-Based Left Ventricular Anatomy and Whole-Chamber Charge Density Mapping for Identifying Ischemic Scar in a Sheep Model

F. Daniel Ramirez, MD, MS, Jeffrey R. Winterfield, MD, FHRS, Pratik Shah, Annelies Vanderper, PhD, Tim Sorrell, Dave Robinson, Xinwei Shi, Derrick Chou, PhD, Eli Ghafoori, Nathan Angel, Leo Mariappan, YOSUKE NAKATANI, MD, PhD, Bruno Sore, Virginie Loyer, Jean-Marc Peyrat, MBA, MSci, PhD, Hubert Cochet, MD, PhD and Pierre Jais, MD. Hôpital Cardiologique du Haut-Leveque, Bordeaux, France, MUSC, Mount Pleasant, SC, Acutus Medical, CA, Acutus Medical, Carlsbad, CA, Hôpital Cardiologique du Haut-Lévêque-CHU de Bordeaux, Université de Bordeaux, Pessac, France, InHeart, Bordeaux, France, Liryx, France, inHEART, Pessac, France, IHU LIRYC (CHU/Univ Bordeaux), Pessac, France, universite de Bordeaux, Bordeaux, France

Background: Conventional electroanatomical mapping systems require serial collection of data points, which can be time-consuming and render characterizing certain arrhythmias challenging. Non-contact ultrasound-based anatomical reconstruction and whole-chamber charge density (CD) mapping has been used to guide ablation in patients with persistent atrial fibrillation. Its value in ventricular chambers has not been explored.

Objective: To test the ability of the AcQMap High-Resolution Imaging and SuperMap System to rapidly and accurately reconstruct left ventricular (LV) anatomy and to delineate ischemic scar.

Methods: An anterior wall infarct was induced in a sheep. After 8 weeks, cardiac MRI was performed and 3D reconstructions of the LV created. An ultrasound and CD mapping catheter was advanced into the LV via transseptal access to generate SuperMap geometries. Scar was defined by late gadolinium enhancement and CD Laplacian amplitude thresholds on MRI and SuperMap, respectively. Corresponding points from both geometries were compared via pairwise analysis.

Results: Total SuperMap acquisition time was 2:27 minutes, resulting in 3,664 anatomical vertices. Scar areas were 17.62 and 18.06 cm² on MRI and SuperMap, respectively. ROC curves demonstrated AUC values of 0.92 and 0.93 for 25% transmural scar and total scar, respectively (accuracy 0.87 for both) (Figure).

Conclusion: Non-contact ultrasound-based LV anatomy and CD mapping was feasible, rapid, and demonstrated a high level of correlation with MRI parameters for identifying ischemic scar in this preclinical model. This technology could be valuable for the treatment of ventricular arrhythmias.

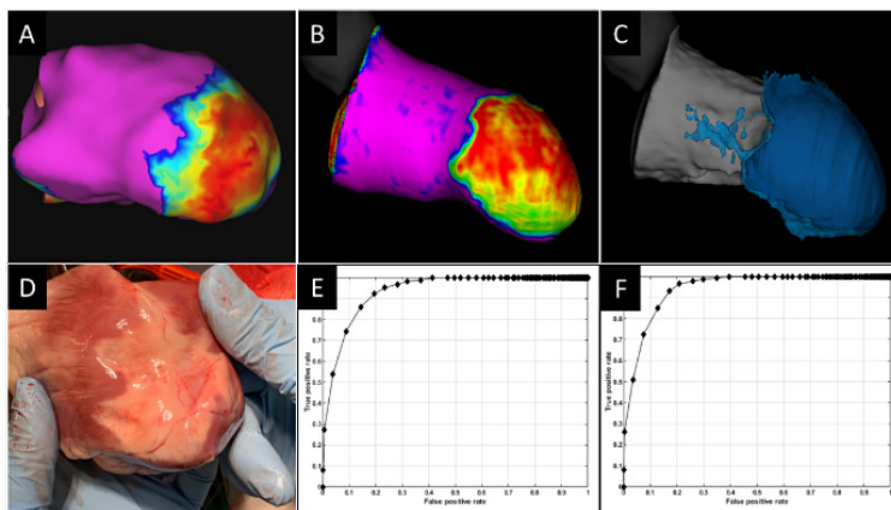


Figure. A LV SuperMap amplitude map (right lateral view). B, C. MRI-based tissue density (25% transmural and total scar, respectively). D. Infarct visible on gross anatomy. E, F. ROC curves of SuperMap amplitude and MRI-based tissue density (25% transmural and total scar, respectively).

Left Ventricular Substrate Characterization by Conduction Velocity in Sinus Rhythm, Ventricular Pacing, and Ventricular Fibrillation

F. Daniel Ramirez, MD, MSc, Jeffrey R. Winterfield, MD, FHRS, Hubert Cochet, MD, PhD, YOSUKE NAKATANI, MD, PhD, Jean-Marc Peyrat, MBA, MSc, PhD, Bruno Sore, Virginie Loyer, Nathan Angel, Annelies Vanderper, PhD, Tim Sorrell, Dave Robinson, Xinwei Shi, Eli Ghafoori, Pratik Shah, Derrick Chou, PhD, Leo Mariappan and Pierre Jais, MD. Hôpital Cardiologique du Haut-Leveque, Bordeaux, France, MUSC, Mount Pleasant, SC, IHU LIRYC (CHU/Univ Bordeaux), Pessac, France, Hôpital Cardiologique du Haut-Lévêque-CHU de Bordeaux, Université de Bordeaux, Pessac, France, inHEART, Pessac, France, InHeart, Bordeaux, France, Liryc, France, Acutus Medical, CA, Acutus Medical, Carlsbad, CA, universite de Bordeaux, Bordeaux, France

Background: Ventricular tachyarrhythmias after myocardial infarction remain a common cause of sudden death. Scar or replacement fibrosis is known to be an underlying substrate for these fatal rhythms. Substrate mapping during sinus rhythm is a low-risk approach to identifying ablation targets for these arrhythmias.

Objective: To explore whether shared areas of consistent conduction slowing or block could be identified irrespective of wavefront direction and rate (during sinus rhythm, ventricular pacing from multiple sites, and ventricular fibrillation [VF]).

Methods: Anterior infarcts were induced in 3 sheep via intracoronary ethanol infusions. Conduction velocities (CV) were computed from charge density using a polynomial fitting method during sinus rhythm and during pacing from 3-5 sites as well as during 4-5 seconds of VF (AcQMap, Acutus Medical). Regions of consistently slow CV were compared to areas of scar as identified on enhanced cardiac MRI.

Results: Localized areas of consistently slow CV were observed in all animals during all rhythms, including VF (mean 24 wavefronts). These areas most often corresponded to border regions of ventricular scar identified on MRI (Figure).

Conclusion: Our study suggests that localized regions of the ventricle with consistently slow CV exist, including during VF, and that they are often found near scar borders. These regions could be identified through interrogative substrate mapping during ventricular pacing from varied sites.

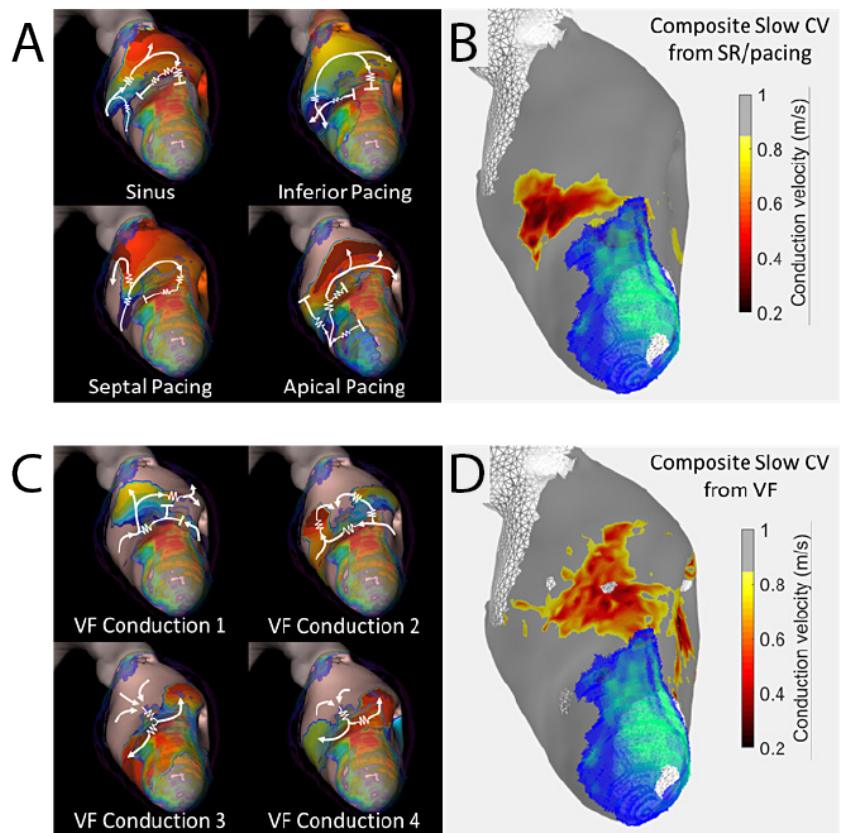


Figure. Example of ventricular substrate mapping using multi-directional wavefronts, revealing sites of abnormal conduction present in SR, pacing, and VF. **A, C.** Propagation sequence for 4 unique substrate-interrogating wavefronts: SR and pacing (panel A), VF (panel C). Anterior scar density shown in color at apex (red: more dense). Snapshot of propagation shown in isochronal color (red: leading wavefront; other colors: preceding wavefront locations, or 'history'). Slow zones delineated by zig-zap lines. **B, D.** Composite maps formed from multiple wavefronts of consistently slow CV from SR and pacing (panel B) and during VF (panel D) (red: slowest). 90% scar transmuralities from MRI overlaid (green: more dense).

Comparison of Intracardiac Non-Contact Calculated Ventricular Electrograms to Measured Contact Electrograms During Mapping: Validating SuperMap Technology

F. Daniel Ramirez, MD, MS, Eli Ghafoori, Nathan Angel, Annelies Vanderper, PhD, Tim Sorrell, Dave Robinson, Xinwei Shi, Derrick Chou, PhD, Pratik Shah, Leo Mariappan, Jeffrey R. Winterfield, MD, FHRS, YOSUKE NAKATANI, MD, PhD, Bruno Sore, Virginie Loyer, Jean-Marc Peyrat, MBA, MSci, PhD, Hubert Cochet, MD, PhD and Pierre Jais, MD. Hopital Cardiologique du Haut-Leveque, Bordeaux, France, Acutus Medical, CA, Acutus Medical, Carlsbad, CA, MUSC, Mount Pleasant, SC, Hôpital Cardiologique du Haut-Lévêque-CHU de Bordeaux, Université de Bordeaux, Pessac, France, InHeart, Bordeaux, France, Liryx, Bordeaux, France, inHEART, Pessac, France, IHU LIRYC (CHU/Univ Bordeaux), Pessac, France, universite de Bordeaux, Bordeaux, France

Background: Complex ventricular tachycardias can be challenging to map due to time required to generate complete maps and the presence of low amplitude electrograms (EGMs). SuperMap (Acutus Medical) is a novel mapping method that temporally aligns multiple non-contact unipolar EGMs detected from a roving multielectrode catheter (AcQMap, 0.70 mm2 electrode areas) then applies a charge density (CD) inverse solution to calculate and display global activation and amplitude maps.

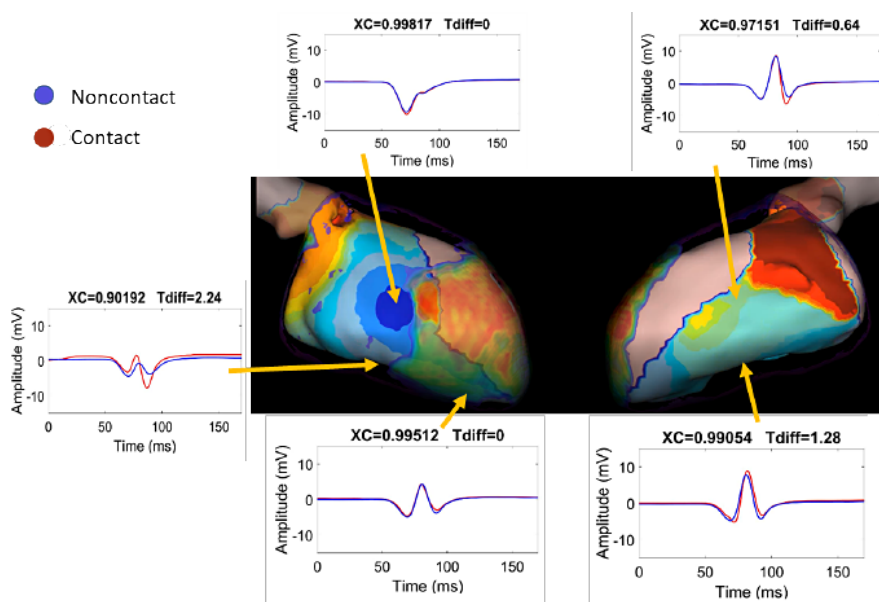
Objective: To compare EGMs derived from roving electrodes (not in contact with LV tissue) to those recorded during electrode contact with the LV wall.

Methods: Anterior wall infarcts were induced via intracoronary ethanol infusions in two sheep. After 8 weeks, ultrasound-based anatomical and SuperMap CD maps of the LV were created using AcQMap multielectrode catheters during sinus rhythm and pacing from septal, lateral, and apical locations. At locations where contact EGMs were recorded, the closest corresponding SuperMap-calculated EGM was used for comparison.

Results: After creating ultrasound-based LV geometries, CD acquisition times were 2.9 ± 0.8 minutes per map. In total, 2285 unipolar voltage EGMs were registered during electrode contact with LV tissue. EGM morphology correlation between non-contact and contact EGMs was 0.93 ± 0.11 with a mean temporal delay of 3.6 ± 6.3 msec in EGM onset (Figure). The degree of correlation did not differ based on direction of activation wavefront.

Conclusion: Non-contact SuperMap-derived ventricular EGMs strongly correlate with conventional contact-based EGMs with respect to morphology and timing.

Figure. Example of unipolar contact and non-contact EGMs comparisons with corresponding locations indicated on an imported MRI anatomy. MR-imaged infarct area is overlaid in translucent color at apex (red: denser). Snapshot of propagation shown in isochronal color (red: leading wavefront; other colors: preceding wavefront locations or 'history').



**For more information please contact your
Acutus Medical representative:**

ACUTUS MEDICAL, INC.

2210 Faraday Ave
Suite 100
Carlsbad, CA 92008
United States
Phone: 888-202-8151
acutus.com

ACUTUS MEDICAL NV

Ikaroslaan 25
1930 Zaventem
Belgium
Phone: +32 2 669 75 00
FAX: +32 2 669 75 01
acutus.com

Prior to using these devices, please review the Instructions for Use for a complete listing of indications, contraindications, warnings, precautions, potential adverse events, and directions for use. The AcQMap and AcQGuide devices are CE Marked and FDA cleared. acutus.com/patents

Acutus Medical®, Acutus®, AcQMap® and AcQGuide® are registered trademarks of Acutus Medical, Inc. This material is the property of Acutus Medical and its subsidiaries. Please do not copy, forward, or distribute this document. Copyright © 2020 Acutus Medical, Inc. All rights reserved.

